Early Gastric cancer (EGC)

POST –DIAGNOSTIC STAGING





Mojgan Forootan, MD
Professor of Gastroenterology, SBMU

October 2024

Indications of ESD

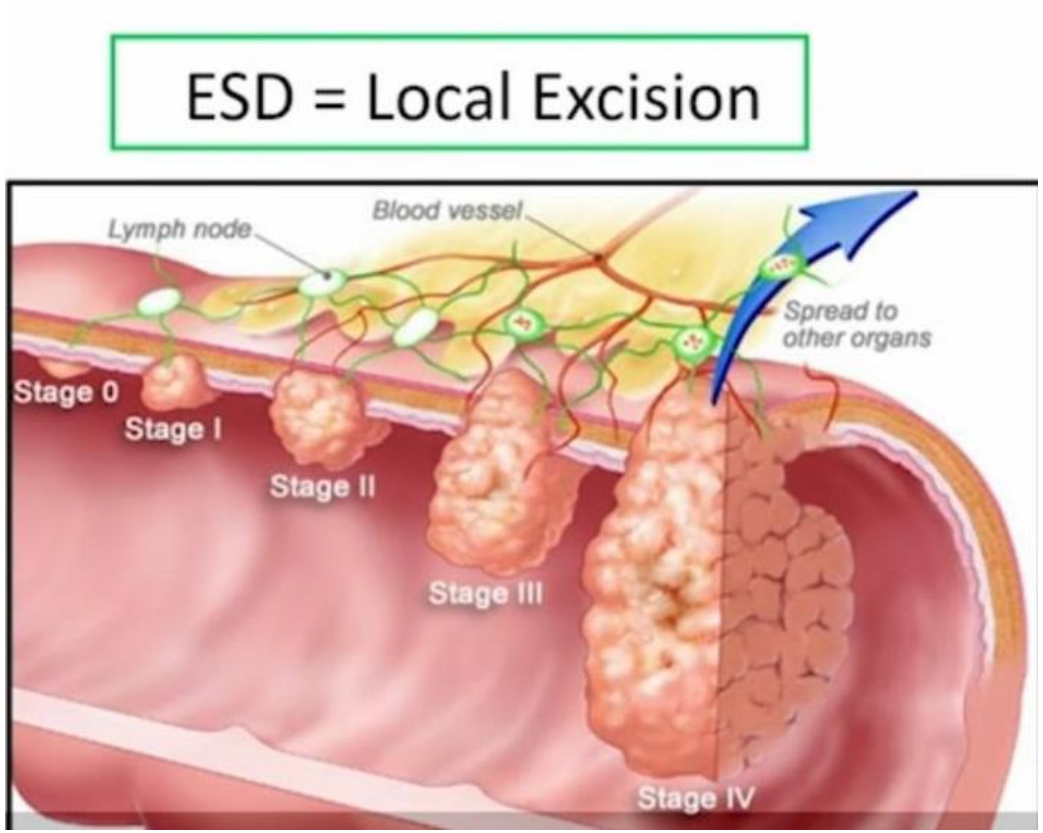

Lesions with minimal risk of lymph node metastasis

- Low grade dysplasia
- High grade dysplasia
- Intramucosal carcinoma
- Superficial submucosal carcinoma

Normal histology of the stomach

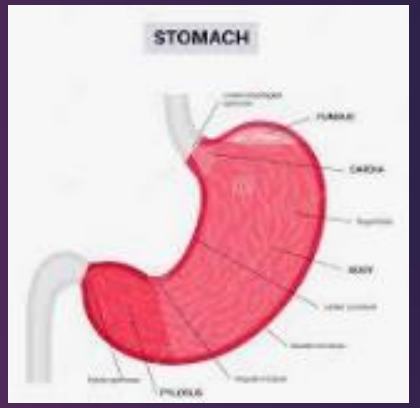

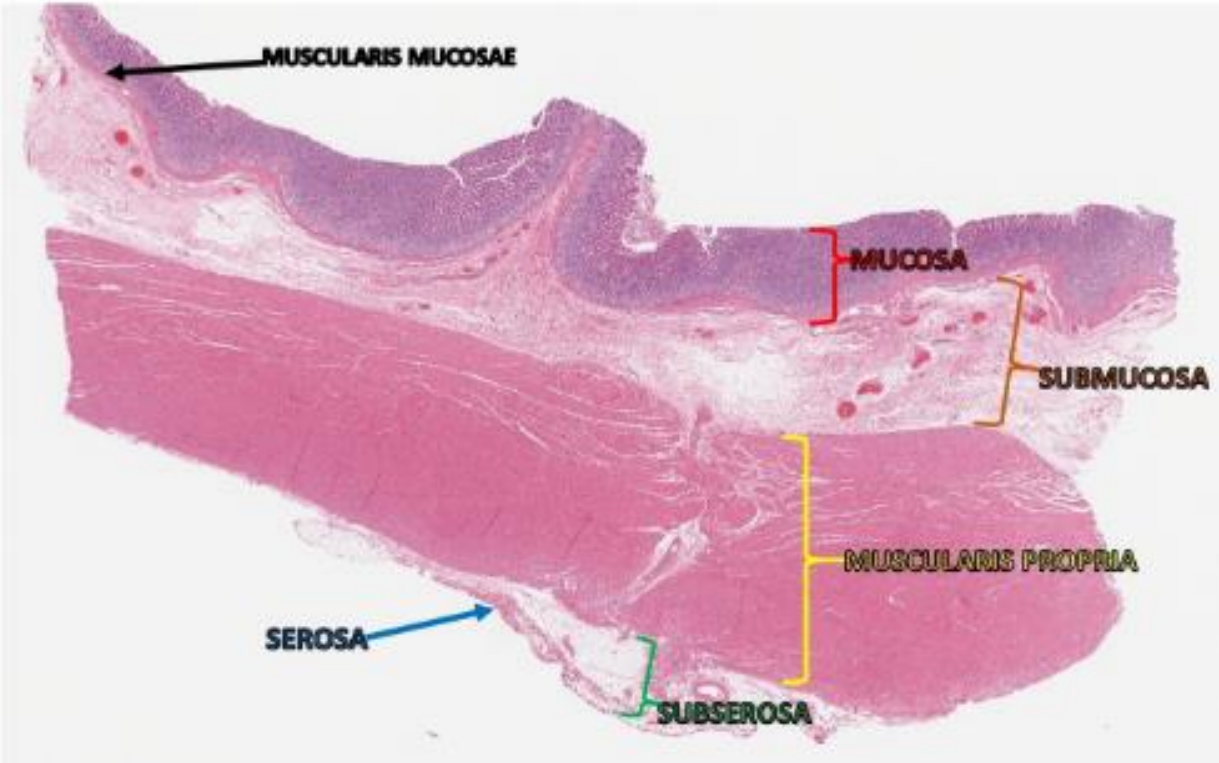

- Layers:
  - Mucosa (with muscularis mucosae)
  - Submucosa (with Meissner plexus)
  - Muscularis propria (outer longitudinal layer, Auerbach / myenteric plexus, inner circular layer, innermost oblique layer)
  - Subserosa
  - Serosa (Am J Surg Pathol 1986;10:48)

Normal histology of the stomach

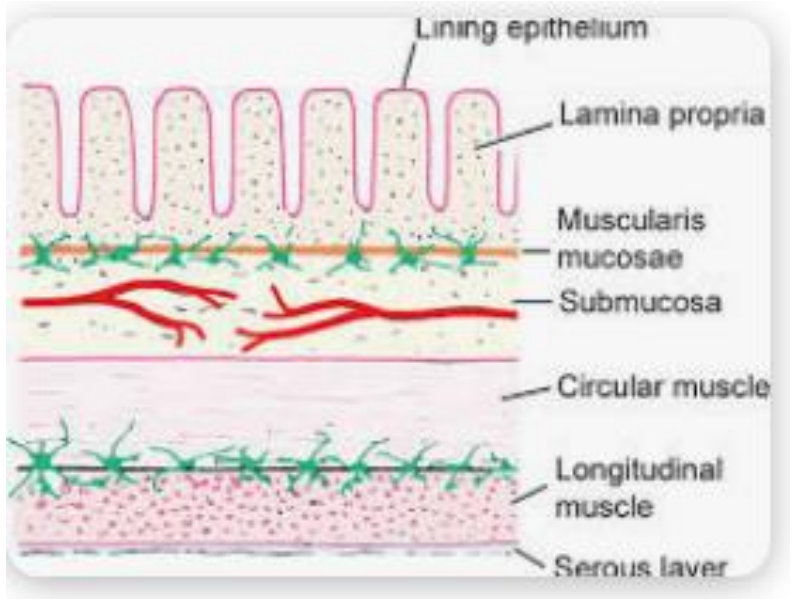

Mucosa

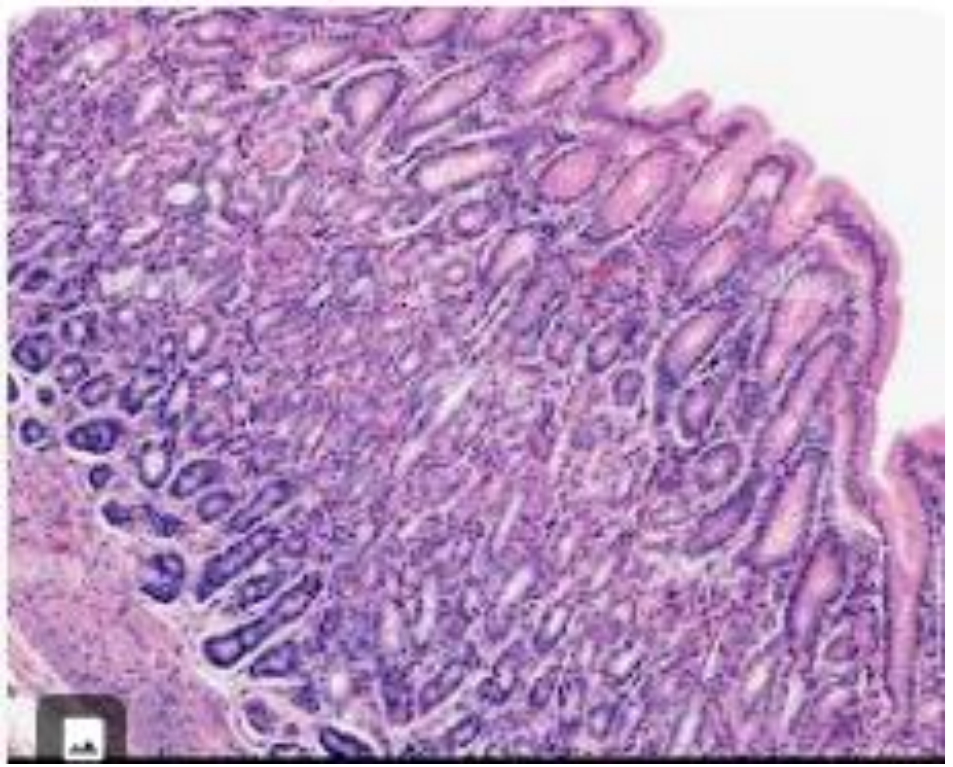

Gastric pits

The lamina propria constitutes the layer of loose connective tissue and interstitial matrix located just below the epithelium. In the stomach, the lamina propria tends to be relatively inconspicuous, filling the interstitial spaces between the tubular gastric glands.

- Components of gastric mucosa:
  - Gastric pits: surface invaginations that function as conduits of secretions; entirely lined by surface mucous (foveolar) cells regardless of anatomic region (Am J Surg Pathol 1986;10:48)
  - Gastric glands: synthesize acids, enzymes and mucins; constituents and their products vary depending on anatomic region of the stomach
    - Glands are organized into isthmus, neck and base (Am J Surg Pathol 1986;10:48)
    - Gastric stem cells are housed in the isthmus and neck portion of glandular mucosa (Wiley Interdiscip Rev Dev Biol 2017;6:e261)

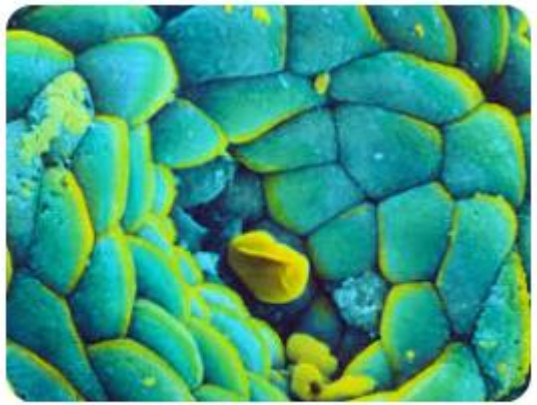

PM Pixels Merch

Stomach Mucosa & Gastric Pit #1...

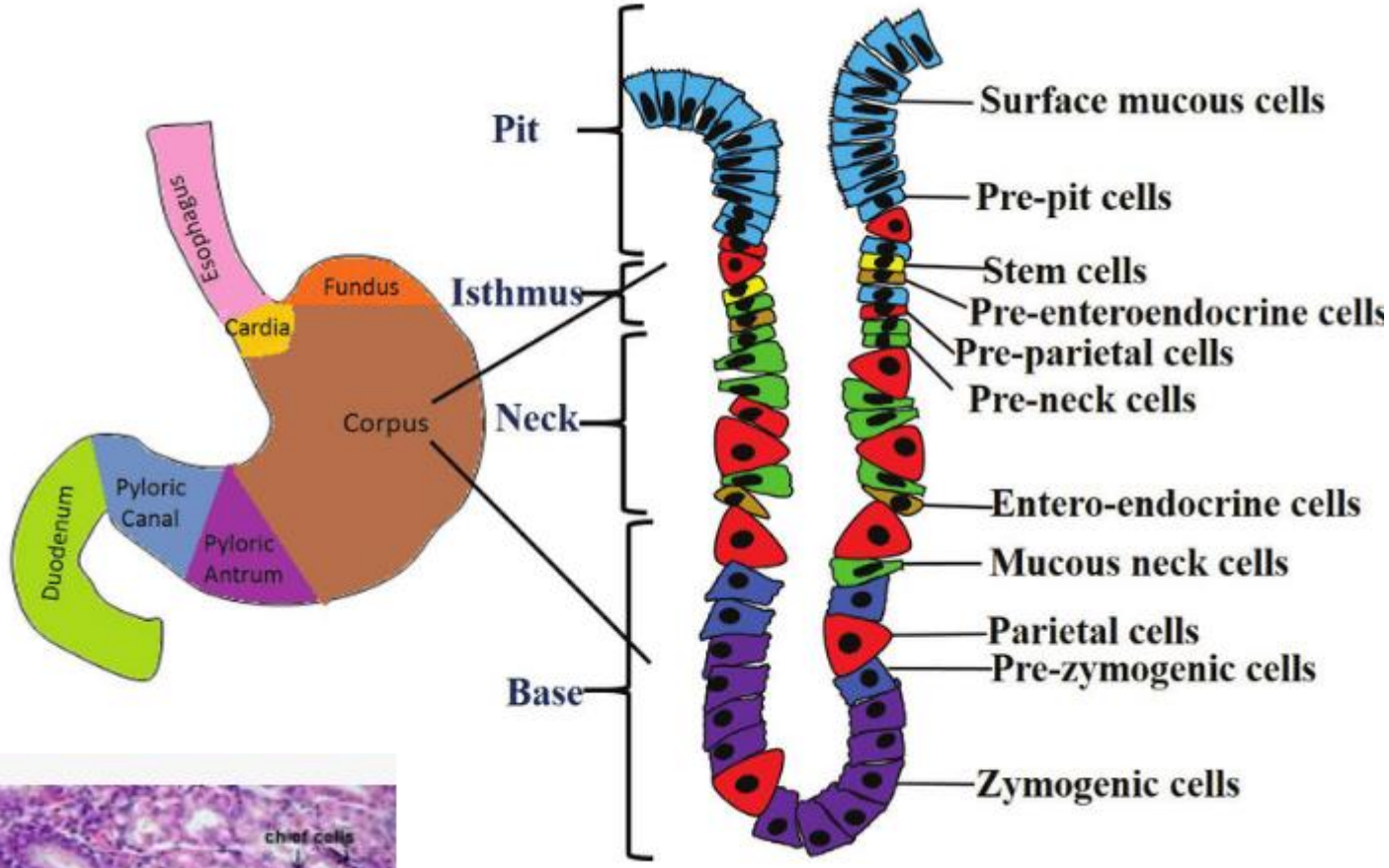

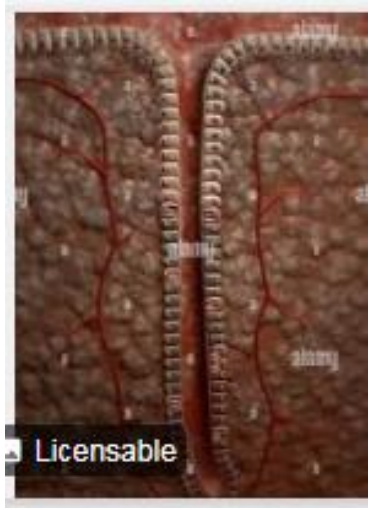

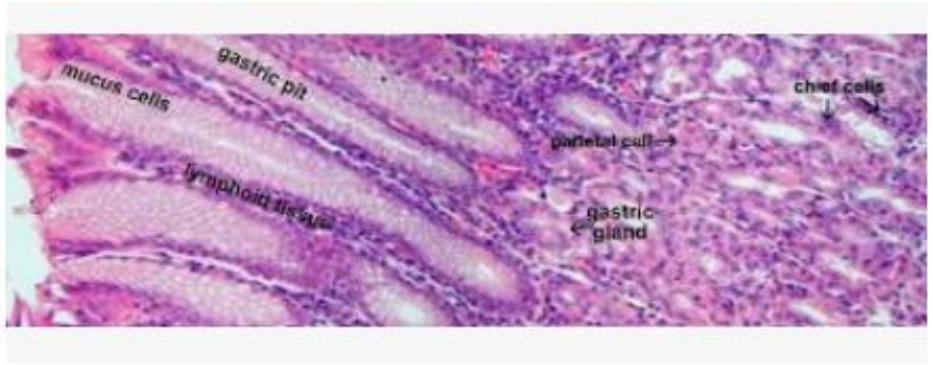

Diagrams depicting the structure of the stomach and gastric epithelial unit including the pit and three glandular regions: isthmus, neck and base. Note that stem cells and their immediate descendants are located in the isthmus. Surface mucous, mucous neck, and zymogenic cells are located in the pit, neck, and base, respectively. Parietal and enteroendocrine cells are scattered throughout.

Gastric pits are

indentations in the stomach which denote entrances to the tubular shaped gastric glands

Upgrading the definition according to CAP



CAP
COLLEGE of AMERICAN PATHOLOGISTS

Early gastric cancer (EGC)

is defined as adenocarcinoma that infiltrates the mucosa or submucosa of the stomach with or without lymph node metastases (T1, any N)

- Mucosal or
- submucosal gastric carcinoma

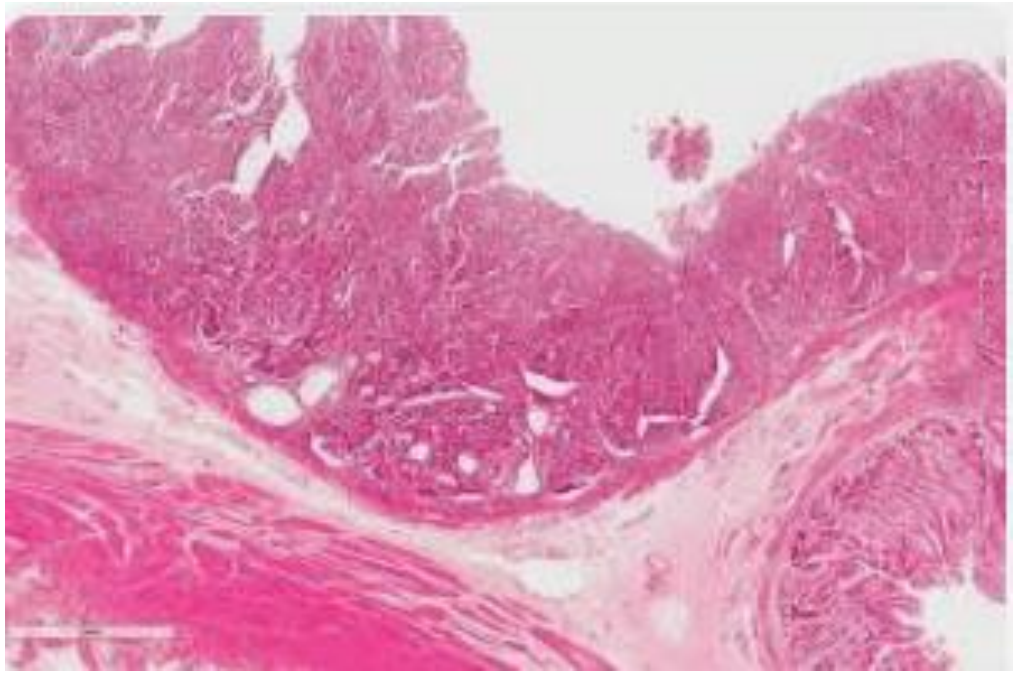

Early Gastric Carcinoma

High grade dysplasia (HGD)
means that there are severely abnormal cells in the inner lining of the stomach. This is sometimes called stage 0.intra epithelial , Formerly called carcinoma in situ ,

Intra mucosal carcinoma : invaded lamina propria

Superficial gastric cancer invaded muscularis mucosa

Early gastric cancer (EGC) :
infiltrates the mucosa or submucosa



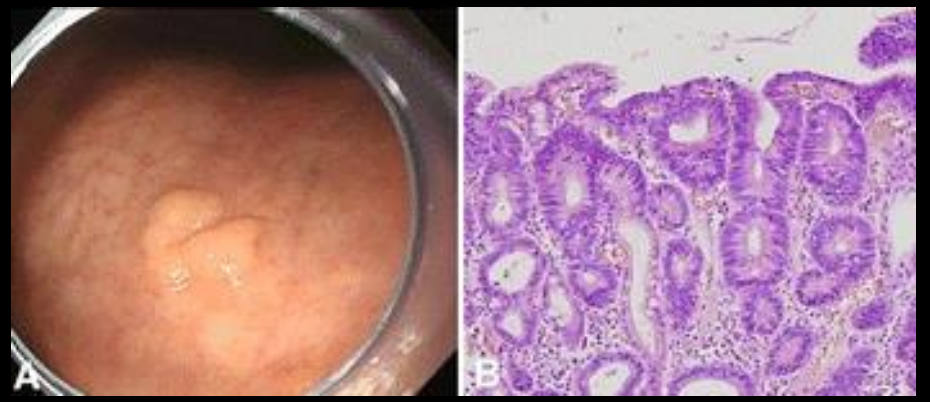

Gastric epithelial dysplasia

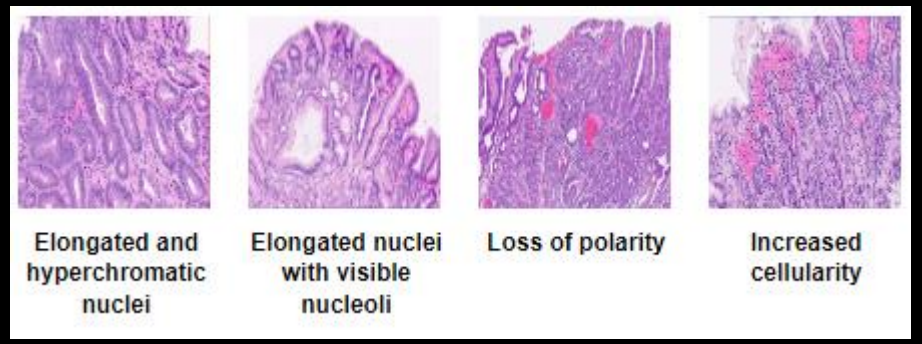

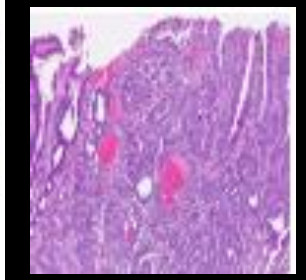

High grade dysplasia

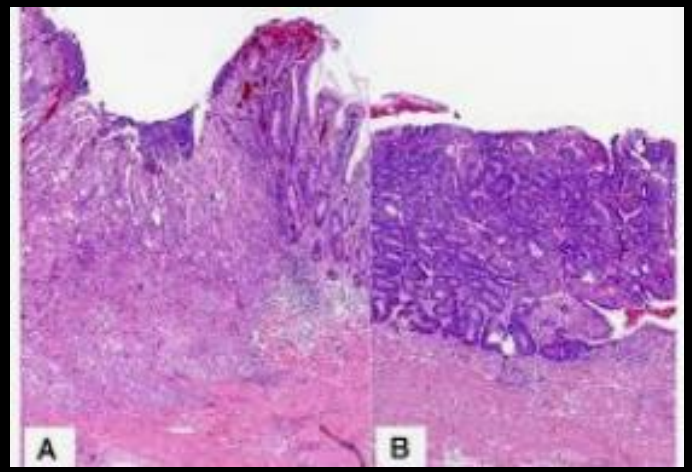

Stomach Intramucosal adenocarcinoma

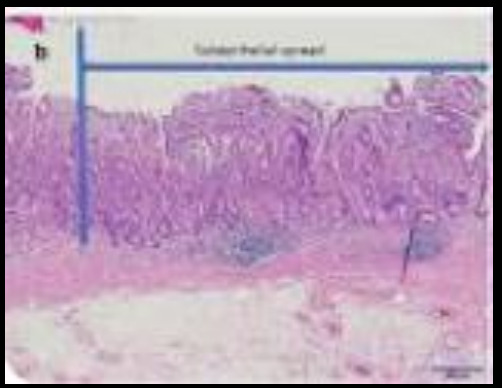

subepithelial (SE) spread from early gastric cancer (EGC)

Preoperative determination of the depth of invasion

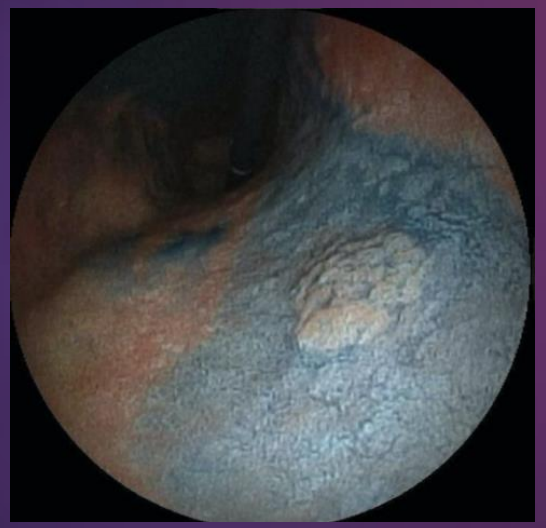

- Gotoda et al. reported that lesions of less than 30 mm that were well-differentiated and showed lack of lymphatic-vascular invasion and submucosal penetration of less than 500 mm were entirely free of nodal metastasis.

1000 micron : 1 millimeter

EGC staging (T1a & T1b)

MUCOSAL OR SUBMUCOSAL GASTRIC CARCINOMA

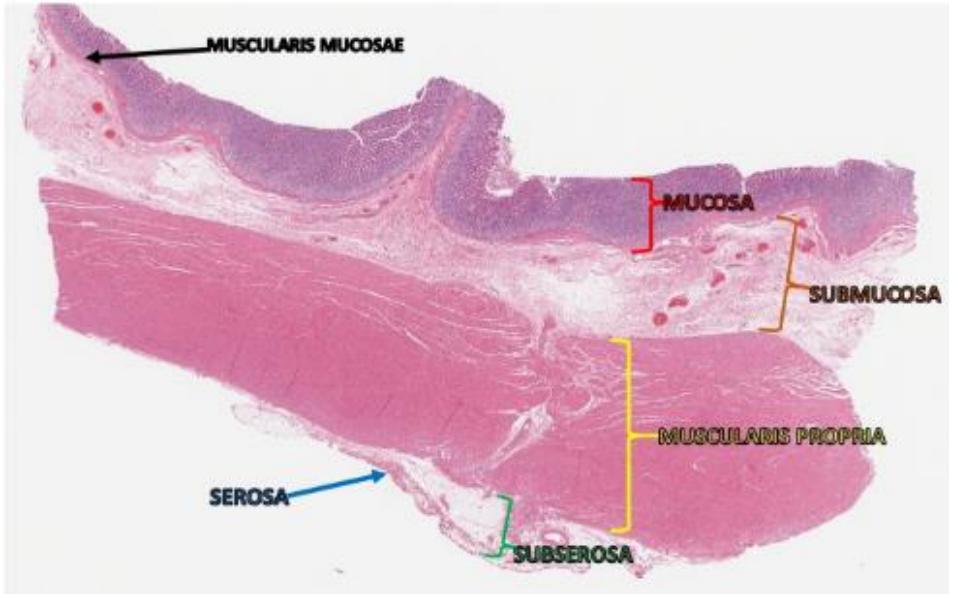

Early gastric cancer (EGC) is defined as adenocarcinoma that is confined to the mucosa or submucosa, with or without lymph node involvement (T1, any N)

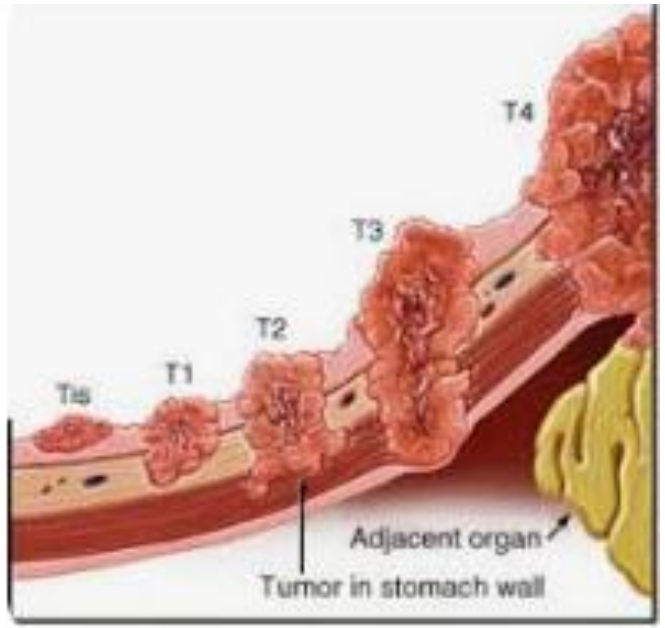

Tis	Carcinoma *in situ*: Intraepithelial tumor without invasion of the lamina propria, high-grade dysplasia
T1	Tumor invades the lamina propria, muscularis mucosae, or submucosa
T1a	Tumor invades the lamina propria or muscularis mucosae
T1b	Tumor invades the submucosa

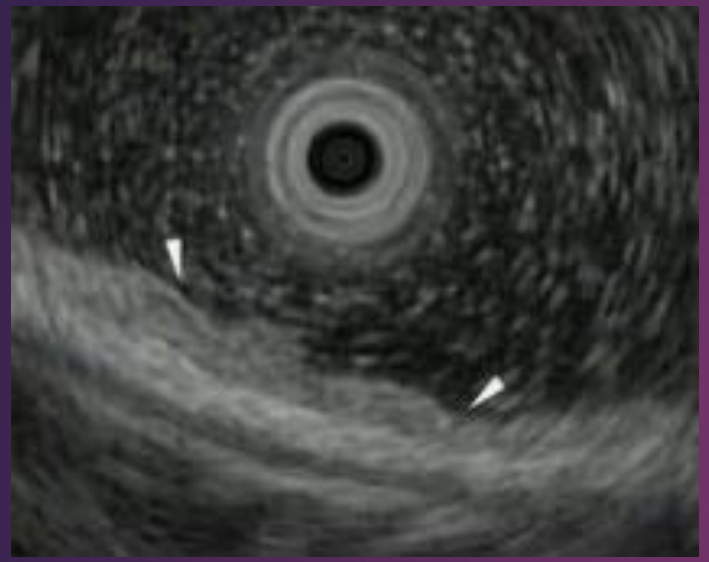

Usefulness of EUS in staging of EGC

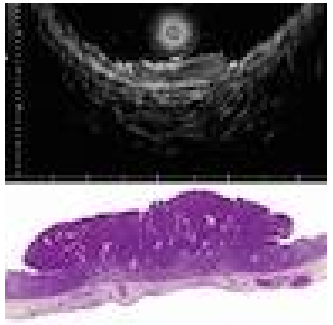

EUS, mucosal gastric cancer

- ✓ Use of EUS for staging varies among centers because some institutional protocols for staging rely on white light endoscopy and histology from ESD specimens for post-diagnostic staging
- ✓ Some Studies suggested that EUS is an accurate method for evaluating the depth of tumor invasion, particularly for T1 gastric lesions
- ✓ EUS can detect locoregional lymph node (N) involvement
- ✓ Use of an EUS miniprobe has been associated with higher accuracy for staging EGC compared with conventional EUS

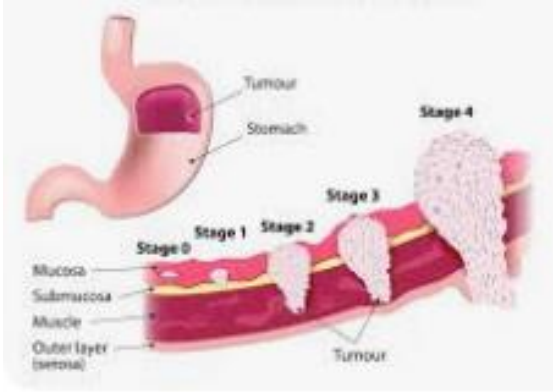

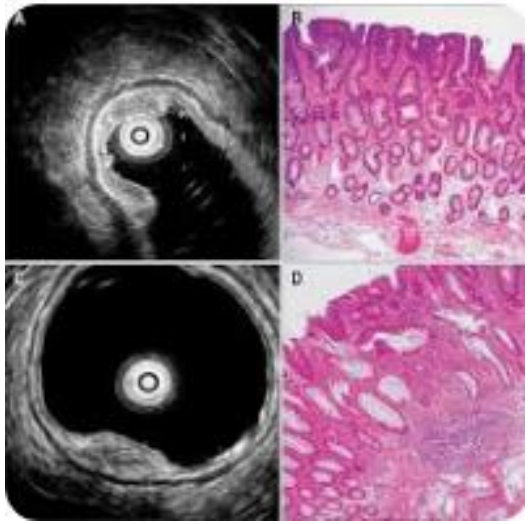





Advanced Diagnostic and Therapeutic Endoscopy for Early Gastric Cancer 2024

EGC staging based on morphology and pathology

Indications of ESD

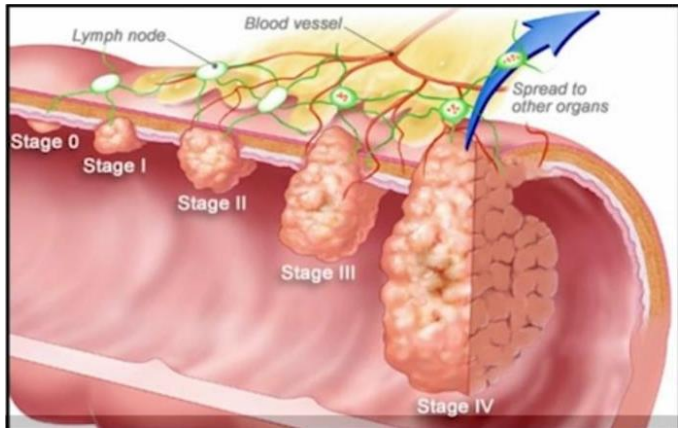

- Low grade dysplasia
- High grade dysplasia
- Intramucosal carcinoma
- Superficial submucosal carcinoma (Sm1)

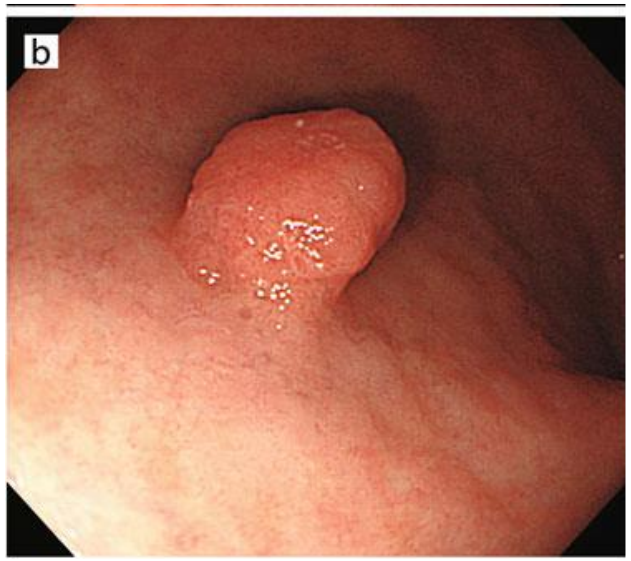

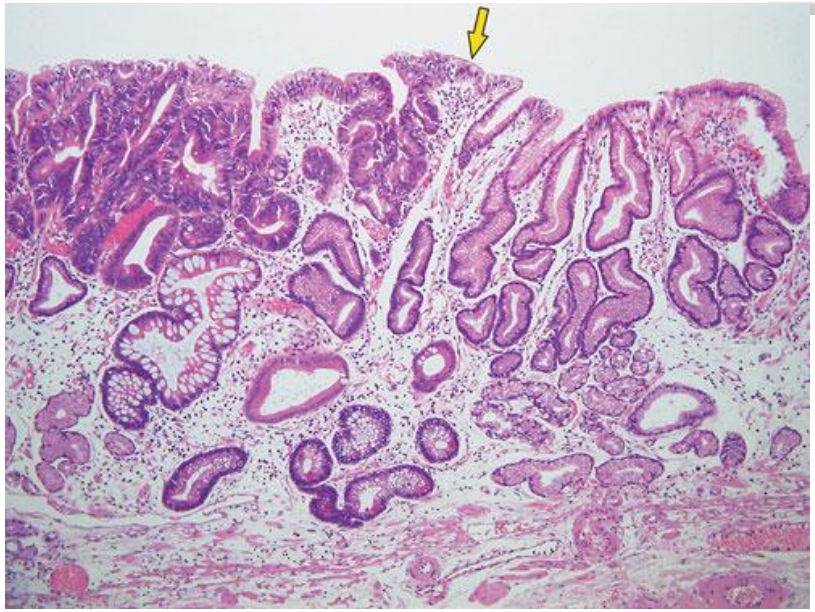

- ✓ *well differentiated*
- ✓ *No lymph vascular invasion*
- ✓ *No Linitplastica*
- ✓ *Size less than 2-3 cm*
- ✓ *No lymph node metastasis*



Tumor characteristics and histology determine
the risk of lymph node metastases and deep sub mucosal invasion

Histology

- ✓ Differentiated tumor

  well , poorly , undifferentiated
- ✓ lymph vascular invasion
- ✓ Linnet or intestinal

For patients with EGC who meet criteria for endoscopic resection, histologic examination of the resected specimen informs the staging evaluation

- ❖ Size of the lesion, depth of invasion, lymph vascular invasion, and lymph node metastasis

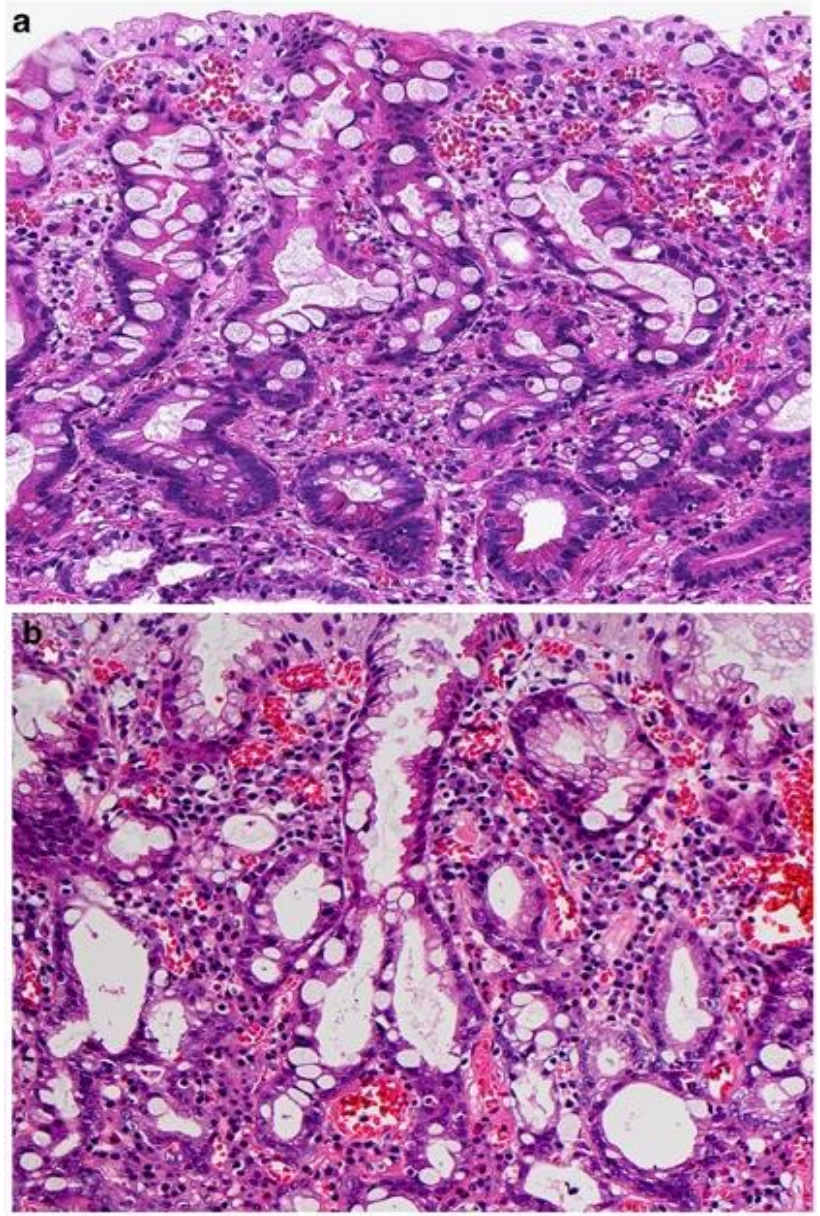

Very well-differentiated gastric carcinoma of intestinal type

Basic Structure of Gastric Adenocarcinoma



Well-differentiated adenocarcinoma (WDA)

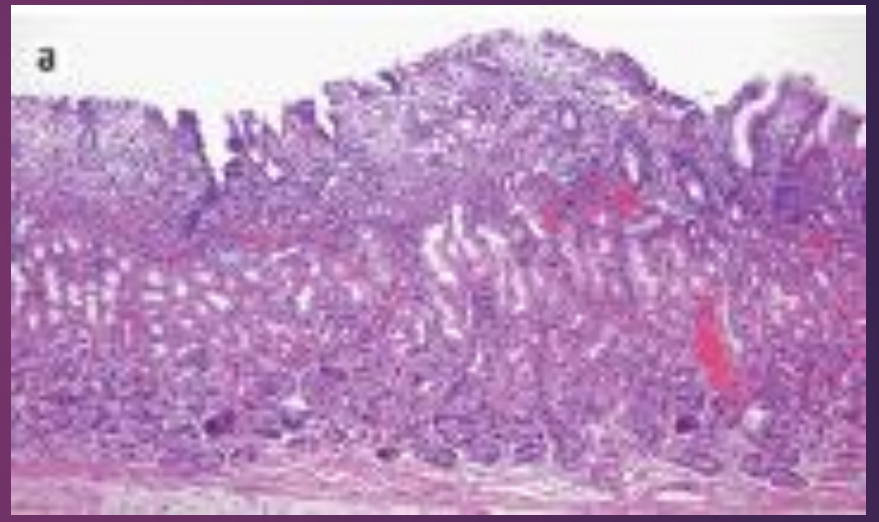

Poorly Differentiated Adenocarcinoma (PDA)

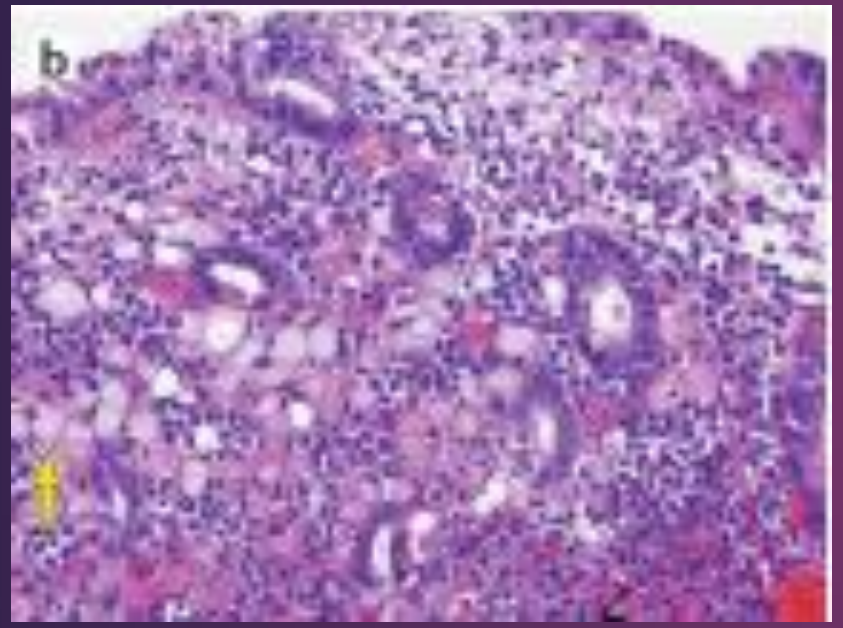

signet carcinoma

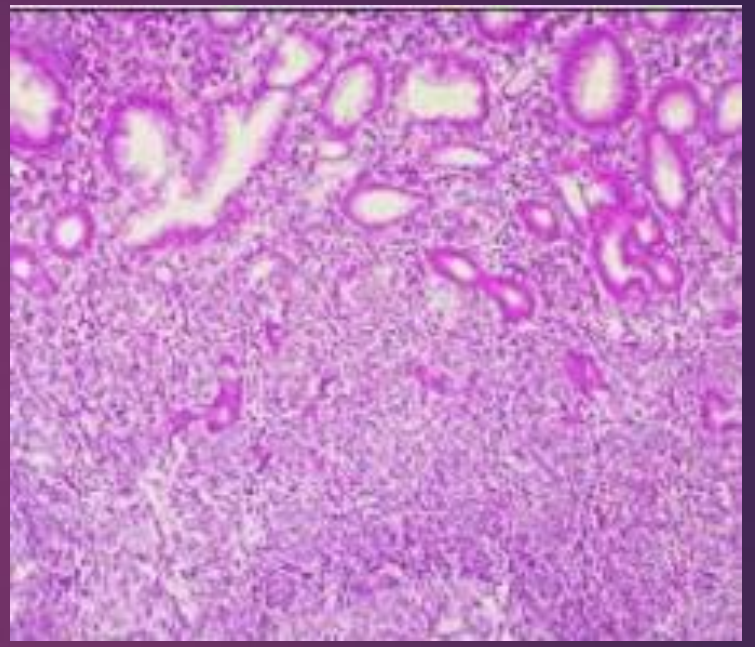

Gastric MALTOMA

Endoscopic morphology

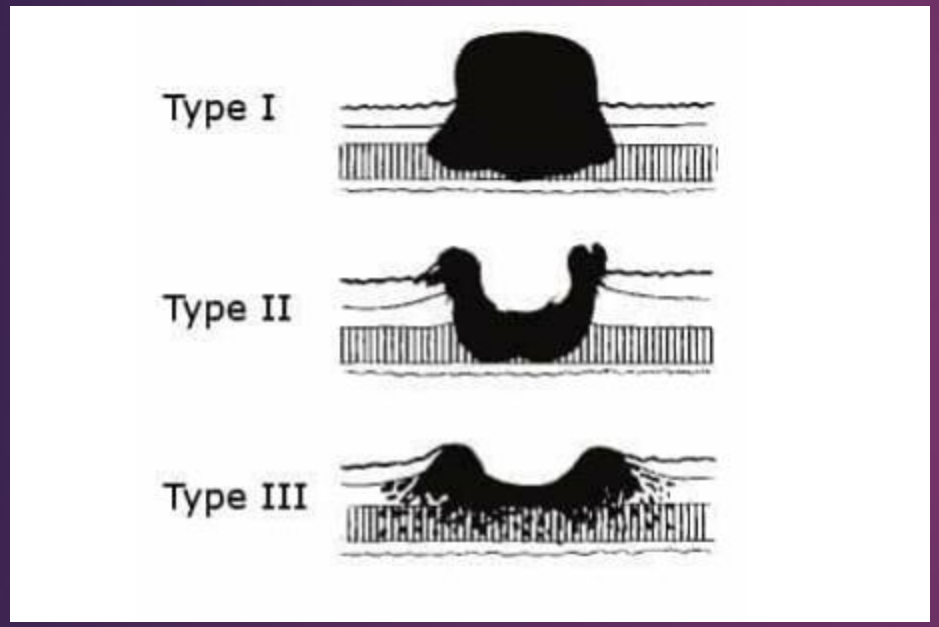



Bormann system

including linitplastica in signet ring cell carcinoma

classifications of types I-IV

Polypoid or protuberant, fun gating growth , ulcerated growth , and diffusely infiltrating tumors

The Paris classification system of superficial gastrointestinal neoplastic lesions

Endoscopic appearance	Description*	Definition	Paris classification¶
Polypoid (lesion protruding from mucosa into the lumen ≥2.5 mmΔ)			
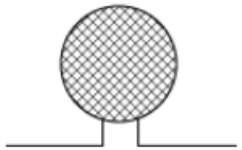	Pedunculated	Lesion attached to mucosa by a stalk	Ip
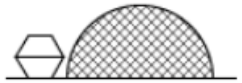	Sessile	Lesion not attached to mucosa by a stalk: Entire base is contiguous with mucosa	Is
Non-polypoid (lesion with little [<2.5 mm] or no protrusion above mucosa)			
	Slightly elevated	Lesion with protrusion but <2.5 mm above mucosa	IIa
	Flat	Lesion without protrusion above mucosa	IIb
	Depressed	Lesion with at least a portion depressed below the level of mucosa	IIc

Type	Subclasses
0-I: Polypoid	0-Ip: Protruded, pedunculated
	0-Is: Protruded, sessile
0-II: Nonpolypoid	0-IIa: Slightly elevated
	0-IIb: Flat
	0-IIc: Slightly depressed
0-III: Excavated	



The Paris endoscopic classification

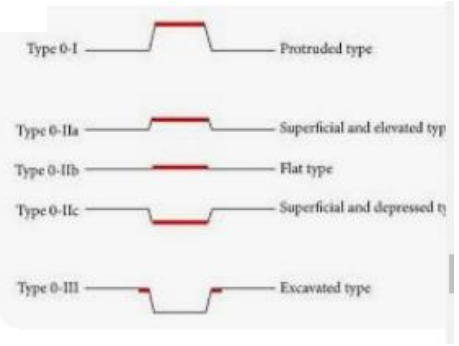

Endoscopic Measuring the Submucosal Depth of Invasion and types of tumor

Size (2-3 cm) , **Ulceration** , **depression** **and** **new and abnormal vessels?** reprehensive of **deep sub mucosal invasion**

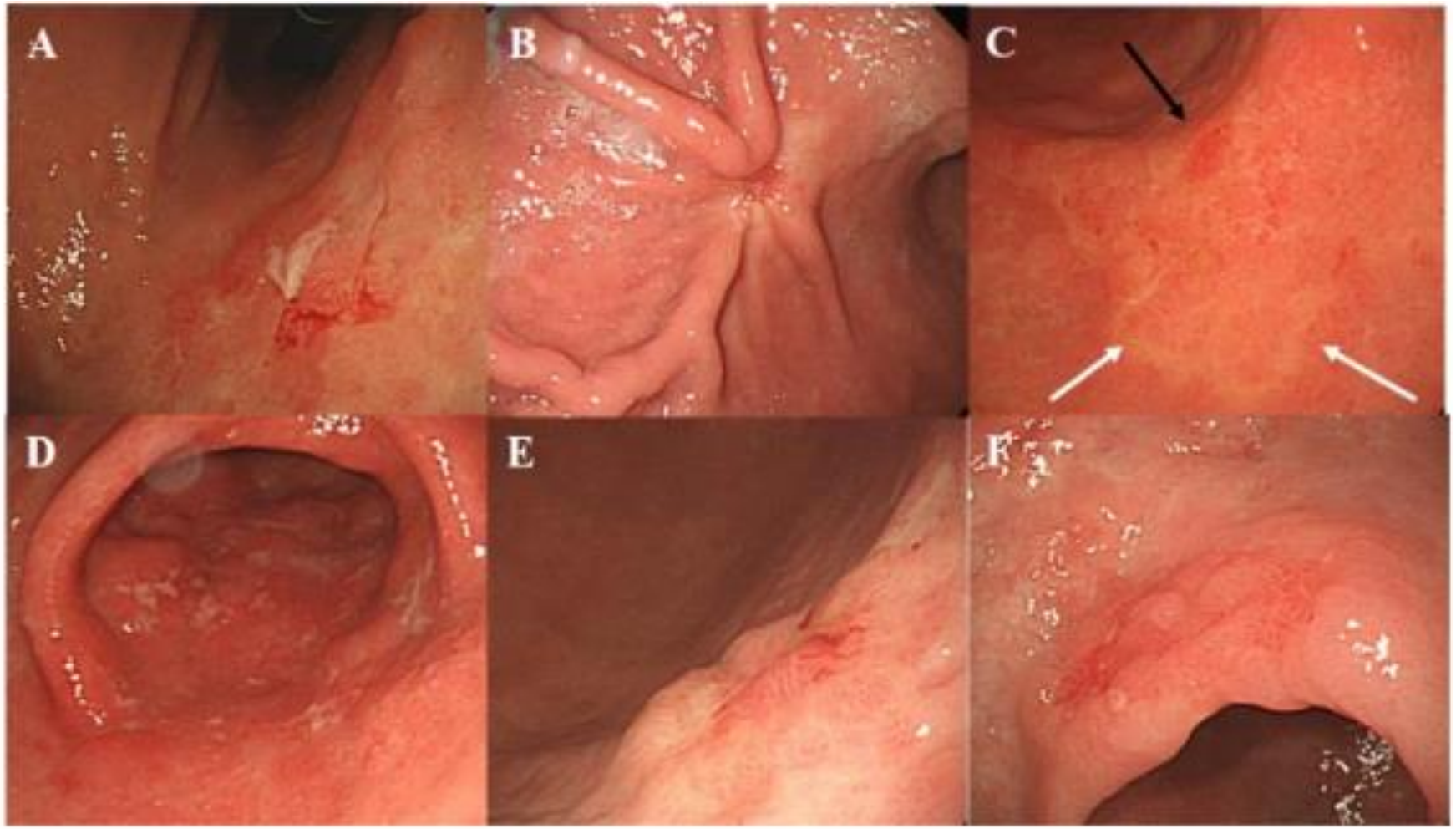

Surface configuration of undifferentiated type early gastric cancer. (**A**) Active ulceration, (**B**). Scarring deformity, (**C**). erythema (black arrow) and discoloration (white arrow), (**D**). Surface erosions with white exudate, (**E**). **central depression** at the elevated type early gastric cancer, (**F**). nodular surface appearance.

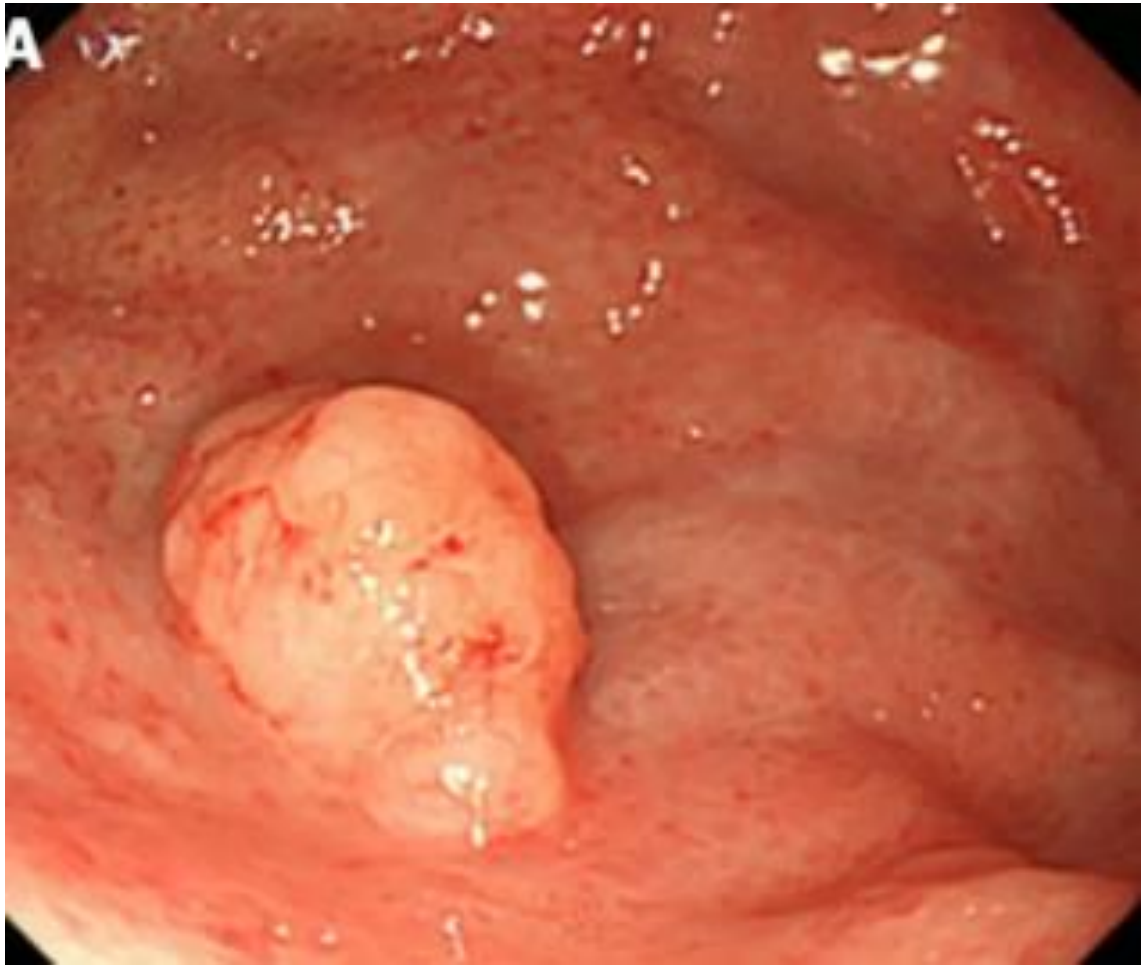

Endoscopic findings of gastric mucosa-associated lymphoid tissue lymphoma. A: An elevated lesion, 10 mm in diameter, was observed in the greater curvature of the gastric fornix; B: Narrow band imaging findings. The mucosa that had lost its glandular structure, appeared shiny and had a tree-like appearance.World J Gastrointest Endosc. Apr 16, 2012; 4(4): 151-156

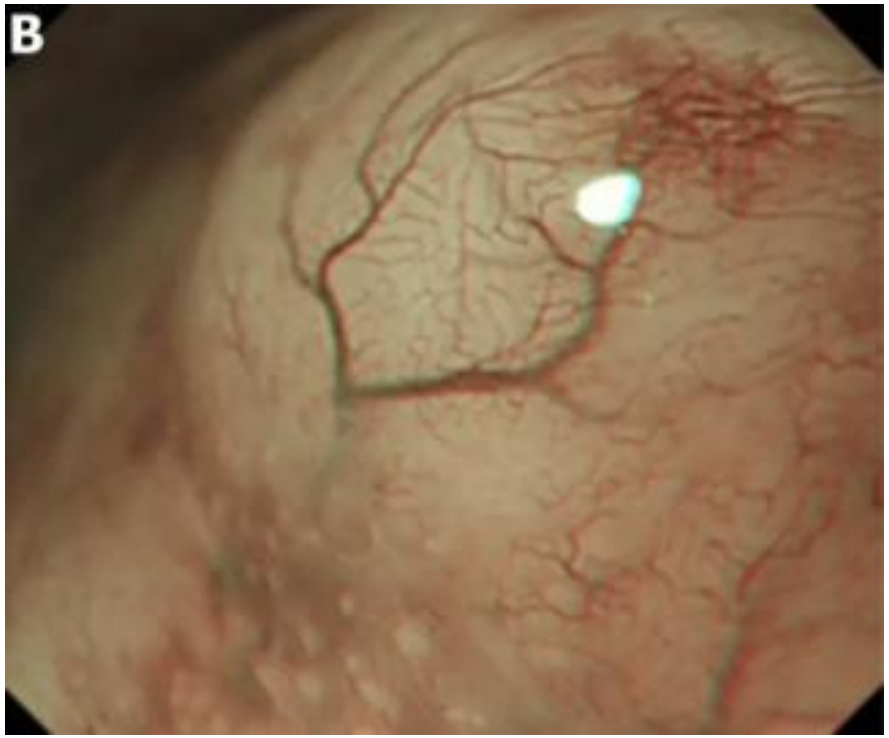

branching abnormal blood vessels

Case Practice

Paris or borrmann / Mucosal (T1a) or sub mucosal T1 b (Sm1 or sm2)

Well differentiated Adeno CA (WDA) 0-I, T1a

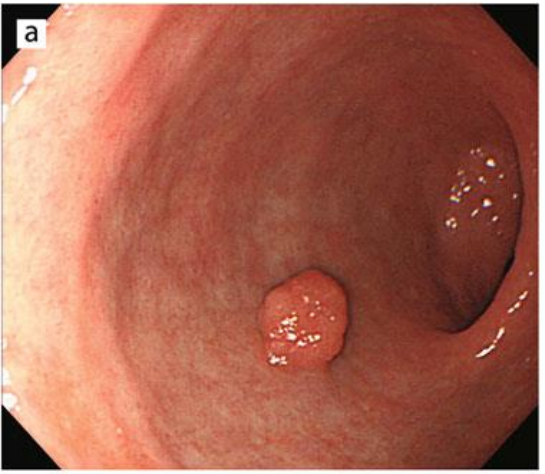

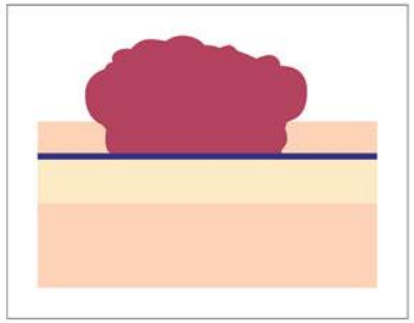

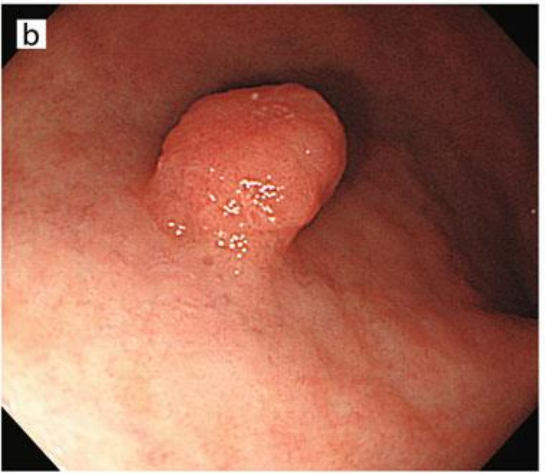

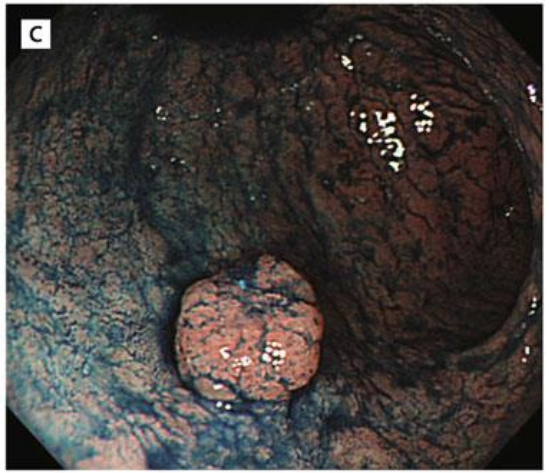

0-IIa, T1a, M cancer



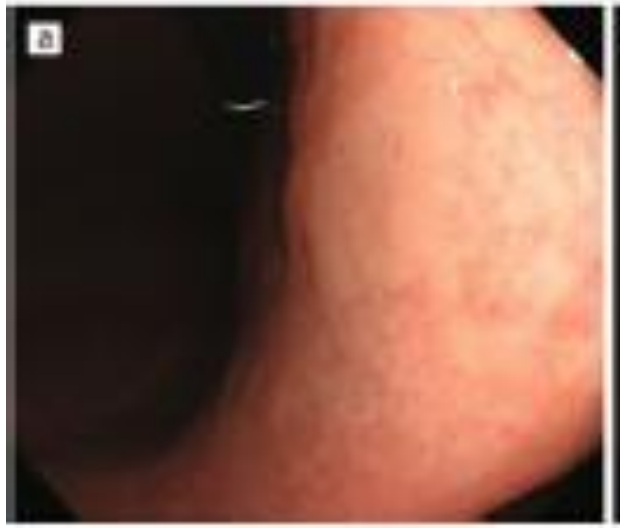



0-I, T1b (SM cancer)

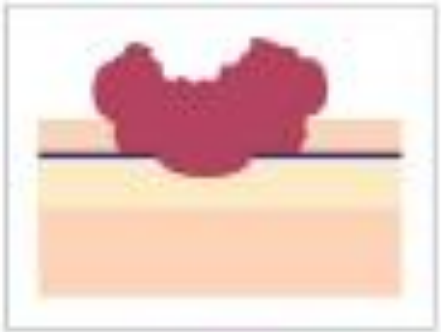

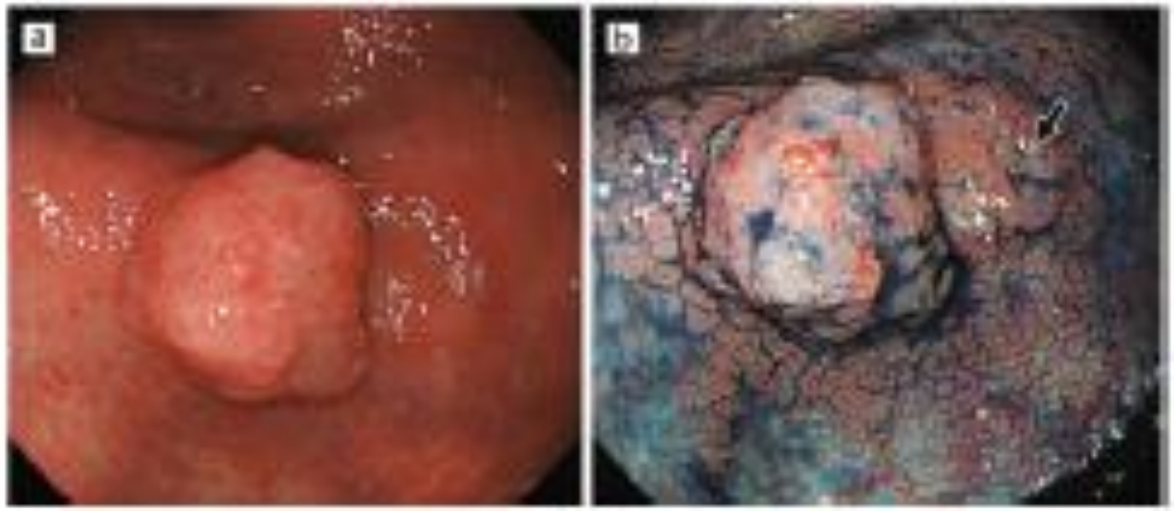

0-I1a, T1b (SM cancer)

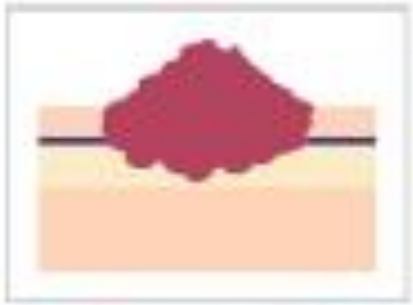



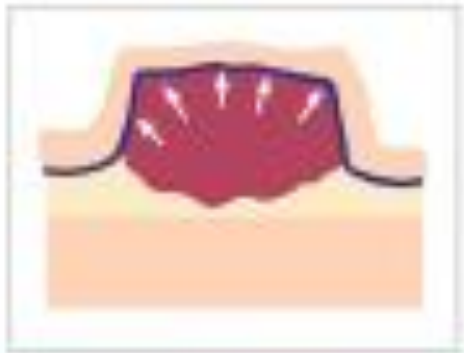

0-IIc, T1b (SM cancer)

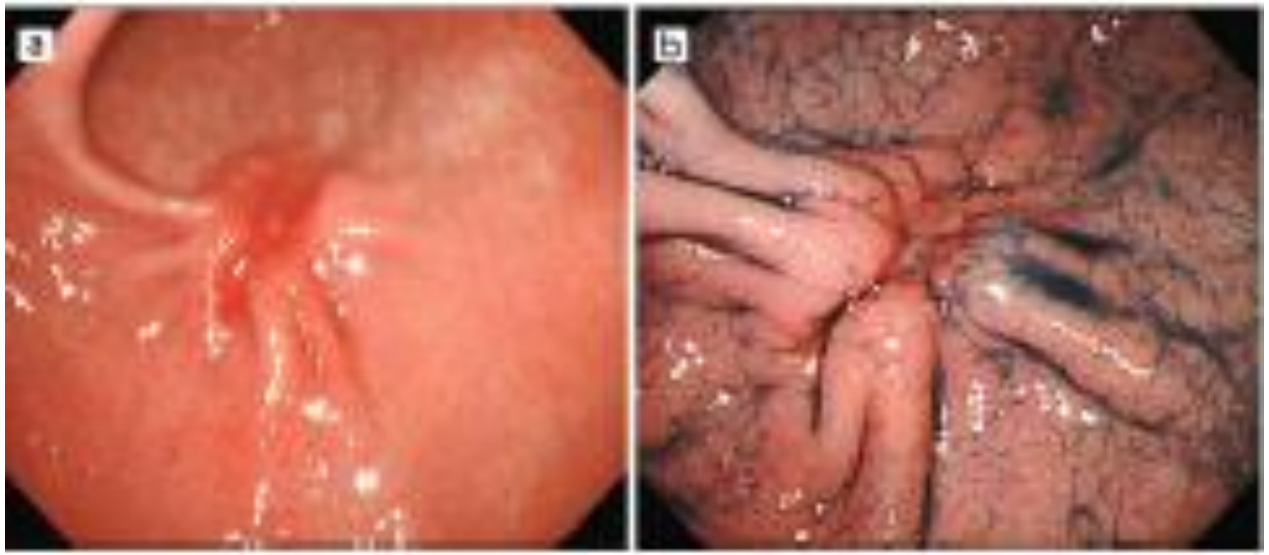

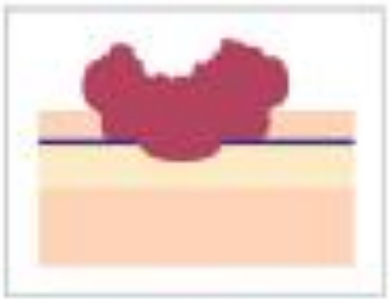

0-I, T1b, SM2 cancer



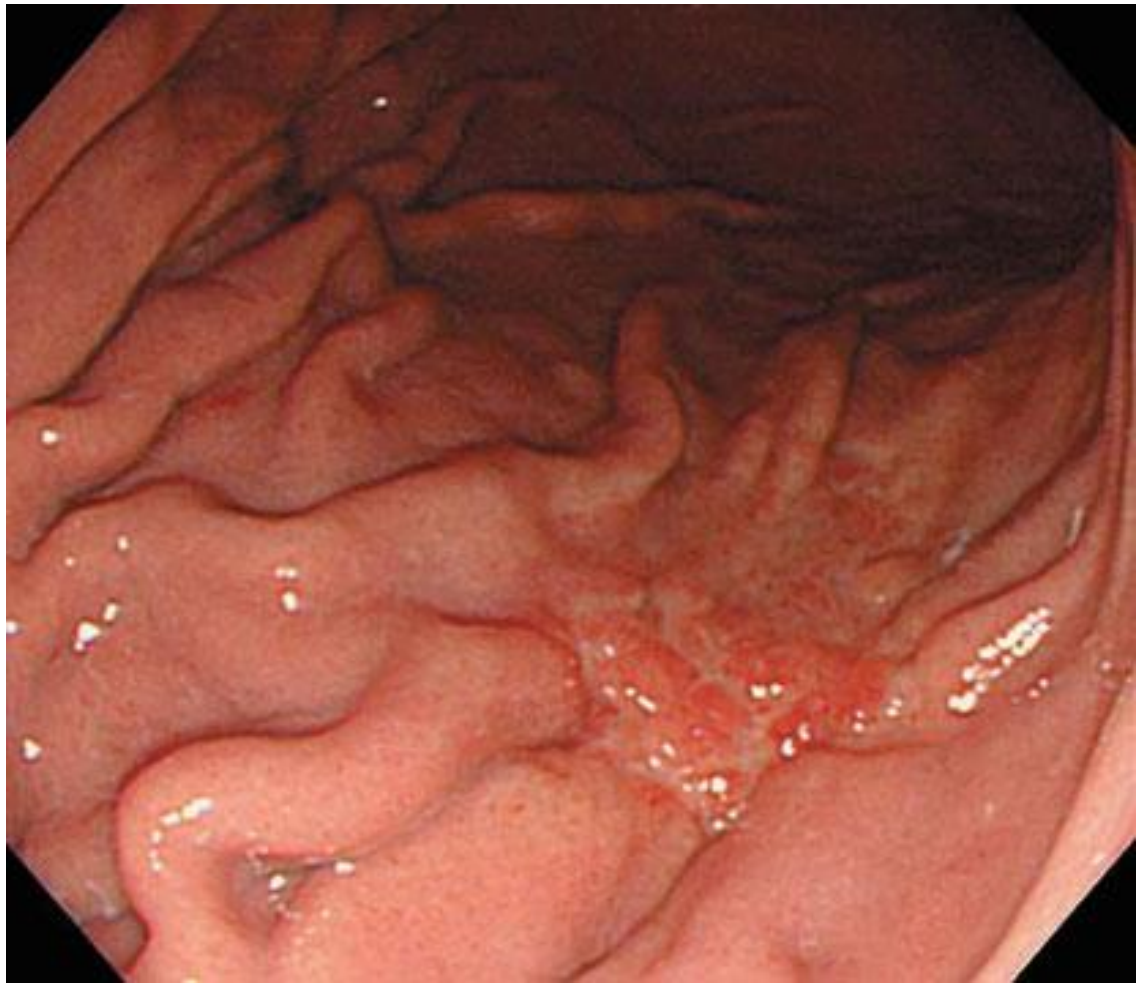

Fold convergence caused by deep invasion of PDA

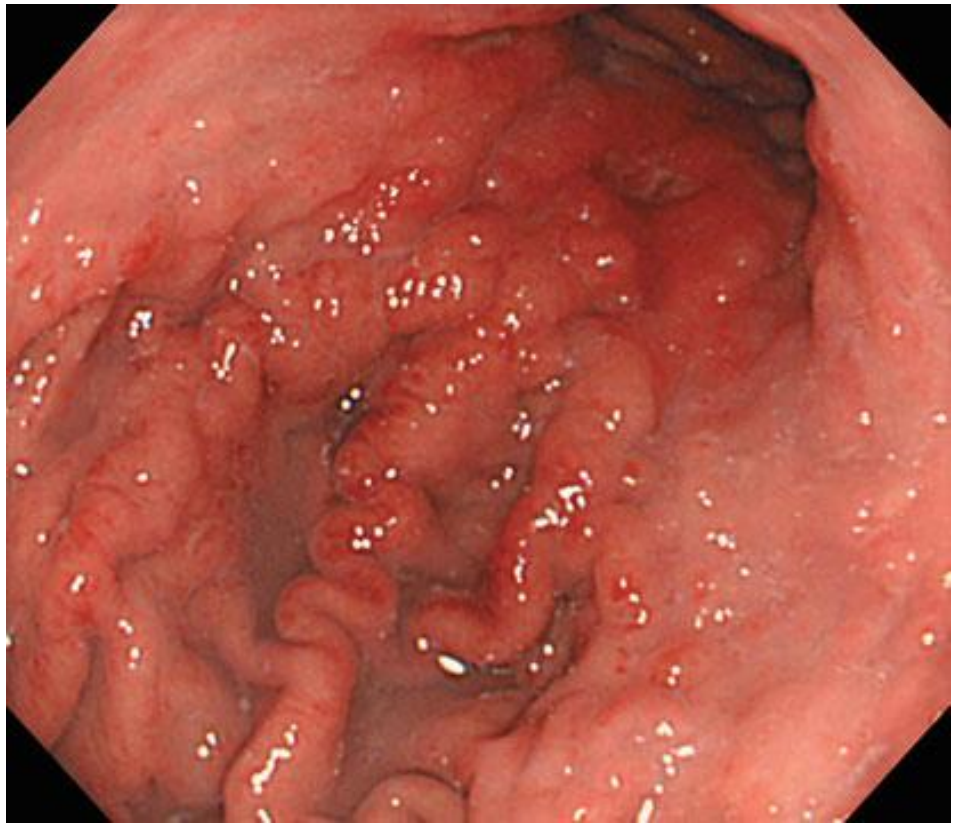

Last word





Thank you